



ST DAVID'S EQUINE
VETERINARY SURGEONS

FACTSHEET

EQUINE BACK PAIN DIAGNOSIS AND TREATMENT

A brief overview of the anatomy of the back

The vertebrae of the spine join together in a complicated way to make up the vertebral column. The spinal cord carries all the nerves to the rear of the animal from the brain and runs through a bony canal through the centres of the vertebrae. Spinal nerves branch off the spinal cord and exit the spinal canal between each pair of vertebrae. These spinal nerves supply each “segment” of the body with sensation and muscle control.

The spine must act as a rigid protective case for the sensitive spinal cord which is easily damaged and act as a rigid pole from which the muscles making up the abdominal wall hang, but must also allow movement to enable the animal to bend its back and transmit power from the hind legs to the body when moving. The joints between the adjacent vertebrae are twofold. Between each pair of vertebral bodies, there is an inter-vertebral disc which is a fibrous pad with a jelly like centre.

This absorbs shock and allows some movement between the vertebrae. There are also a pair of so called “facet joints” between each vertebra, one each side, which allow restricted movement in a limited direction. Although the movement at each inter-vertebral joint is limited, when the small movements at each joint are added together, the result is a flexible column which can bend and twist in a number of directions.

Each vertebra has bony projections on each side (transverse processes) and on the top (dorsal spinous processes) which act as sites for ligament and muscle attachment. Between each dorsal spinous process is an inter-transverse ligament and running along the top of the dorsal spines is the supraspinous ligament which runs from the back of the head to the base of the tail. These ligaments limit the degree to which the spine can flex and so protect the spine and its contents from injury.



The pelvis joins to the spine at the so called sacro-iliac joints which are paired joints, left and right. They are mainly made up of various strong ligaments, although there is also a small true fluid joint as well. The main role of this joint is to transmit power from the hind legs to the rest of the body.

The common clinical conditions occurring in the horse's back

There are a number of clinical conditions that can occur in the horses back. These can then lead to various signs of back pain or poor performance.

- *Desmitis (strain) of the supraspinous or intertransverse ligaments.*
- *Desmitis (strain) of the ligaments which make up the sacro-iliac joint.*



- *Kissing spines.* This condition occurs when the dorsal spinous processes of adjacent vertebra (which should be separated by a space in the normal horse) are too close together and rub against each other. In some cases, this occurs simply because the horse is born with the dorsal spines crowded together. In other cases, the impingement is caused by an abnormal posture. The abnormal posture is often caused by another factor which causes the horse to dip its back. This can be a hind limb lameness, sacro-iliac pain or a poor fitting saddle.
- *Arthritis of the vertebral facet joints.*

Diagnosis

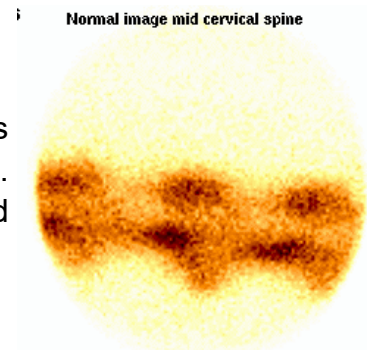
There is no one diagnostic tool that can diagnose all of the conditions affecting the horse's back and the tools cannot replace the value of a good examination of the back. However, diagnostic tools are necessary to specifically diagnose the condition and the site of pain to allow appropriate treatment.

Scintigraphy (bone scanning)

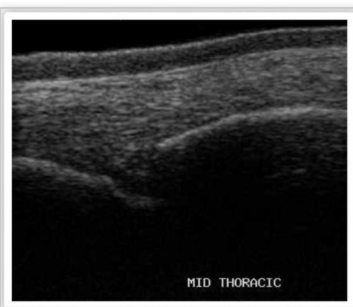A short acting radio-labelled isotope is injected that is incorporated for a short time into bone where there is an active remodelling process. Bone remodelling is going on all of the time but can be most active where there is disease such as fracture, arthritis, etc. The radioactivity is detected by a gamma camera and the active sites of bone metabolism show up as hot spots. Scintigraphy is useful to identify bone disorders of the back such as sacro-iliac disease, kissing spines and arthritis of the facet joints.

X-ray examination

X-ray examination also examines the bony structures of the back and is most useful to diagnose kissing spines and facet joint arthritis. Unfortunately, the sacro-iliac joint is too deep and encased in bone for good X-ray pictures of this region to be possible.



Ultrasound scanning



Ultrasound is most useful to diagnose lesions of the soft tissues of the back such as desmitis (strain) of the supraspinous ligament. However, although ultrasound cannot penetrate through bone, it gives an accurate picture of the surface of bone and so can also be very useful to diagnose facet joint arthritis and abnormal, strained attachments of ligaments onto bone (enthesiopathy). The latter can occur in the attachments of the supraspinous ligament onto the summits of the dorsal spinous processes.

Regional anaesthesia

Injection of local anaesthetic into a region is useful to diagnose pain in a region and joint block of the sacro-iliac region or infusion of local anaesthetic in the interspinous space between the dorsal spines of the vertebra is often used as a diagnostic tool to confirm the significance of lesions seen on X-ray or ultrasound.



Treatment of back pain

The success of a medical treatment programme for back pain in the horse depends crucially on addressing several of the factors that affect the posture of the horse and its way of going, not just on pain relieving treatments or injections. If one treatment is carried out alone the rate of success is much reduced. Because of this it is crucial that treatment be undertaken by a team of people working together – a so called multidisciplinary approach. Communication and co-operation between vet, physiotherapist, farrier, saddle fitter and rider/owner is essential.

Veterinary and physiotherapy aspects

The treatments that the vets can administer are intended to provide temporary relief of pain to allow a course of rehabilitation exercise that changes the horses posture and way of going. A course of laser therapy administered by the physiotherapist also acts in this way. Horses with back pain tend to develop a way of going that allows them to cope with chronic pain. Often this involves the horse using its forelimbs to pull itself along rather than using the power of its hind end. They tend to dip the back and develop a “lordotic” posture. The muscles of the back and hindlimbs waste away through under-use. Once pain relief has been given, we usually design a course of rehabilitation exercise to increase the strength of the abdominal muscles (core muscle stability), increase the muscle support around the sacro-iliac result in arthritis of the vertebral facet joints later.

There can also be immediate post-surgical complications such as wound breakdown and damage to the spinal nerves that exit the spinal canal between each pair of vertebrae. We have had good results with medical treatment of this condition and would tend to consider the surgery only in cases where medical treatment has failed.

Farriery Aspects

An important part of the treatment of back conditions is the restoration of good posture to the horse that allows it to use itself in the correct way. An important part of this is to provide good foot balance all round, particularly in the hind feet. Many of the horses we see with chronic back pain have collapsed heels and reverse rotation of the pedal bones in the hind feet. These conditions tend to make them stand under behind. Correction of these conditions is very important to the success of treatment of back pain in the horse.

Saddle Fitting

Once we have treated a horse with back pain, ensuring that the saddle is of a good fit is essential. It goes without saying that if we put a saddle that rubs or pinches onto a back where there is a medical problem it will not be long before the horse starts to resent exercise again. Consequently ongoing checking of the saddle by a good saddle fitter is essential.

Treatment of back pain requires attention to a number of different factors and a multidisciplinary approach. Many of the conditions causing pain in the horses back can be managed by medical treatment and it is often possible to relieve pain and allow the horse and rider to perform successfully again without the need to resort to surgery.